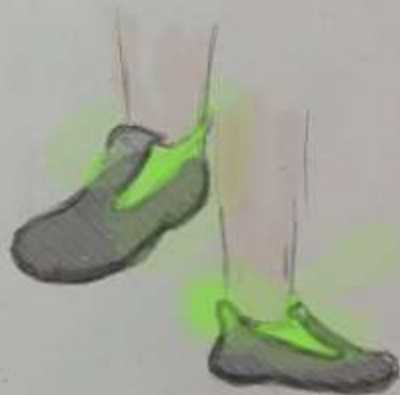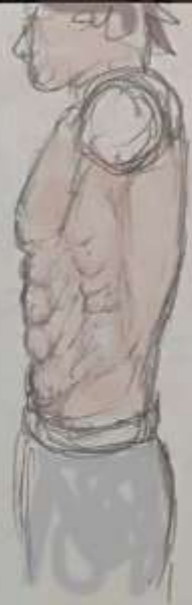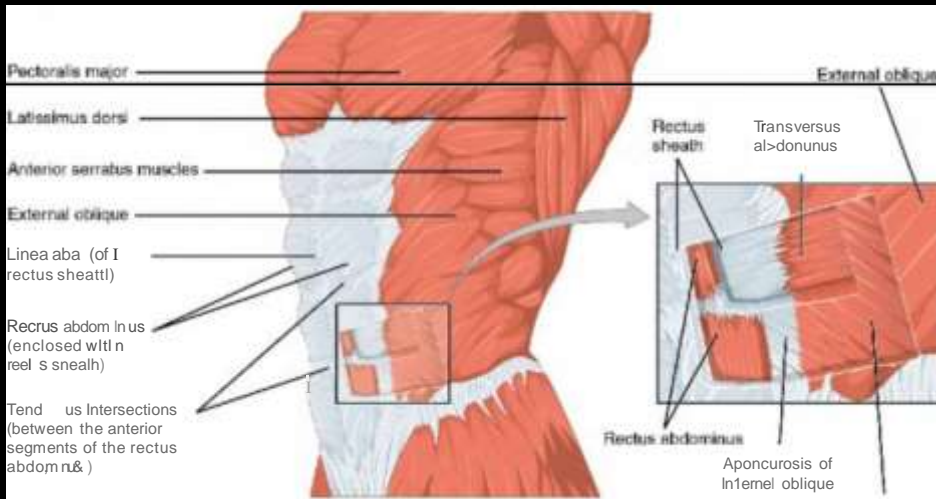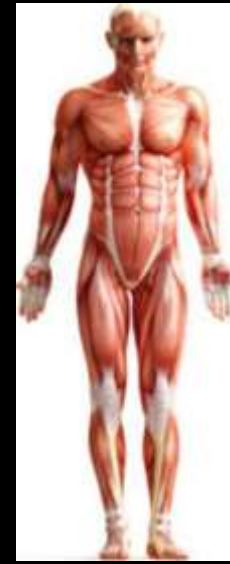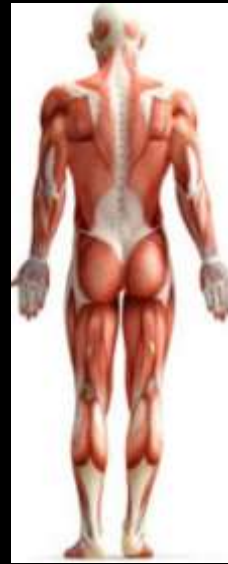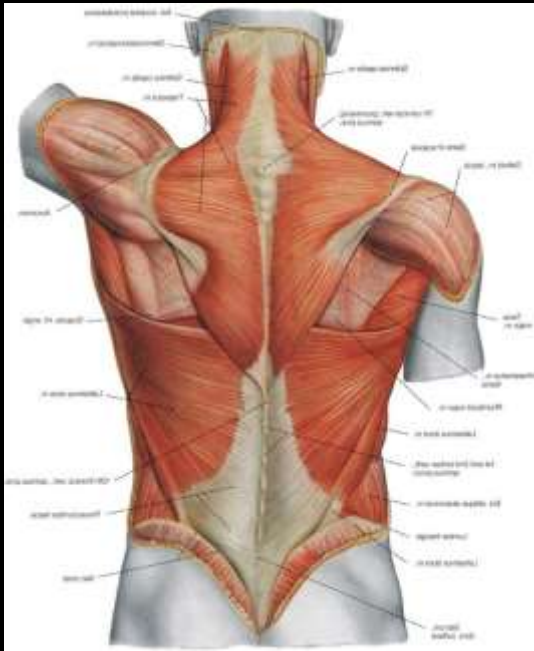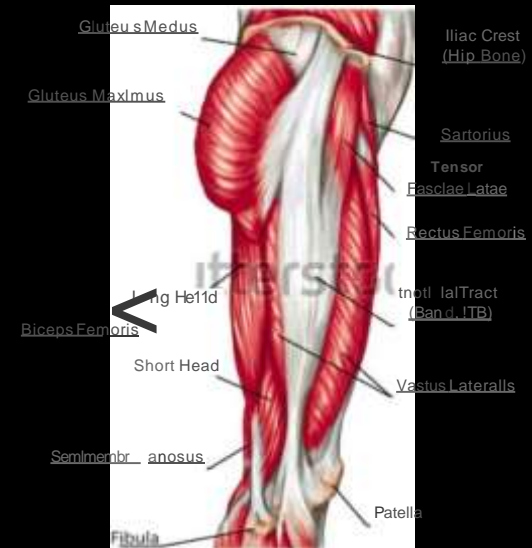


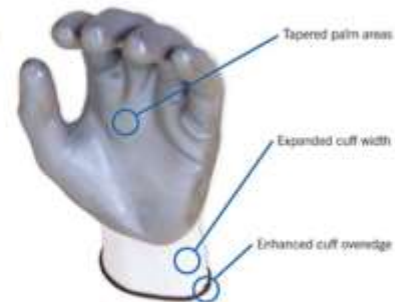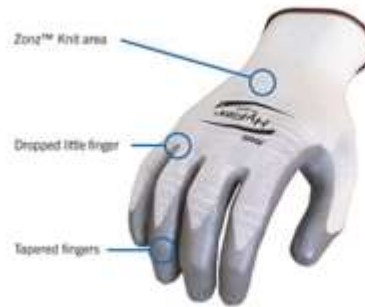(a) Superficial and deep abdominal muscles (anterior/lateral view)

Internal oblique











Thank You